az monica

Orthopedisch centrum SPM

Geneeskundige dagen Antwerpen

Behandeling cuff scheuren

Dr. N. JANSEN

Rotator cuff tears in young patients

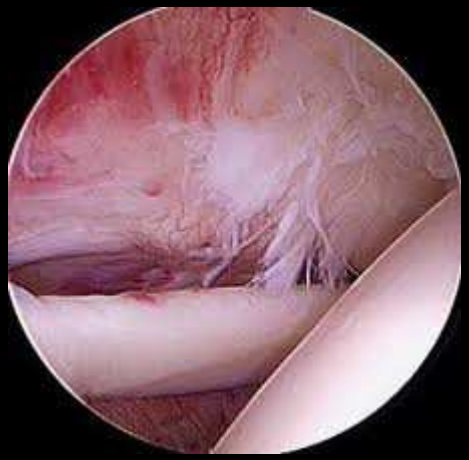

A different disease

az monica
Orthopedisch centrum SPM

Journal of shoulder and elbow surgery july 2015

Rotator cuff tears in young patients

a different disease than rotator cuff tears in elderly patients

az monica
Orthopedisch centrum SPM

J shoulder elbow surgery(2015)

systematic electronic search

37 studies , 11 included

nonprospective level 4 studies

336 subjects

mean age : 22-33 years

men : 91,7%

az monica
Orthopedisch centrum SPM

Cuff tears < 40 years

2 SUBGROUPS

- post-traumatic FT tear supraS
- unique subgroup : ELITE throwers

Internal Impingement

az monica
Orthopedisch centrum SPM

Internal Impingement

fysiological contact between GT and posterosuperior glenoid when the shoulder is in abduction – external rotation

However in the throwing athlete the contact may become pathologic through it's repetitive nature

az monica
Orthopedisch centrum SPM

Internal Impingement

Anterior instability theory

Postero-superior instability theory

Scapular dyskinesie

az monica
Orthopedisch centrum SPM

Internal Impingement Theory

Anterior instability theory

- abnormal anterior translation of the humeral head (Frank Jobe)
- hyperangulation during extension (Chris Jobe)
- excessive ext rotation during late cocking phase (Jimmy Andrews)

az monica
Orthopedisch centrum SPM

Internal Impingement Theory

Postero-superior instability theory

progressive postero-inferior capsular tightness creates a superior shift

of the humeral head and a

peel back phenomenon of the posterosuperior labrum in the cocking phase (Morgan and Burkhart)

az monica
Orthopedisch centrum SPM

Peel back lesion

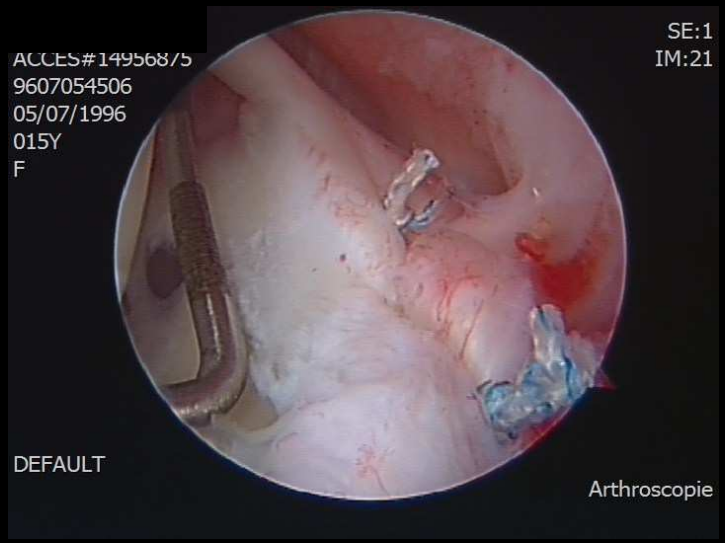

az monica
Orthopedisch centrum SPM

Scapular Dyskinesie

inadequate scapular rotation and tilt may cause the conflict (Ben Kibler)

az monica
Orthopedisch centrum SPM

Internal Impingement Spectrum

POSTERO-IMPINGEMENT SIGN

- 90° shoulder abduction
- 90° elbow flexion
- maximal external rotation
- APPREHENSION post shoulder pain

az monica
Orthopedisch centrum SPM

Internal Impingement Spectrum

GIRD

glenohumeral internal

rotation deficit

!!! Throwing athletes often have an increased int rotation and a decreased ext rotation (when pathologic ??)

az monica
Orthopedisch centrum SPM

Internal Impingement Spectrum

Cuff strength

look for weakness of the cuff

az monica
Orthopedisch centrum SPM

Internal Impingement lesion

Due to repetitive contact : pathology :

tear posterosuperior labrum

articular cuff tear

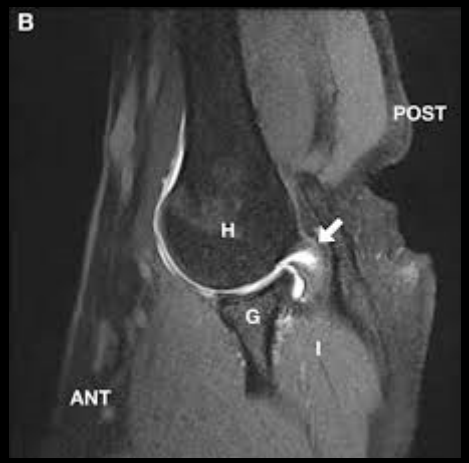

az monica
Orthopedisch centrum SPM

INTERNAL IMPINGEMENT TEAR

Majority of tears are partial articular sided cuff tears, commonly posterosuperior at the junction of the infraspinatus and supraspinatus insertions

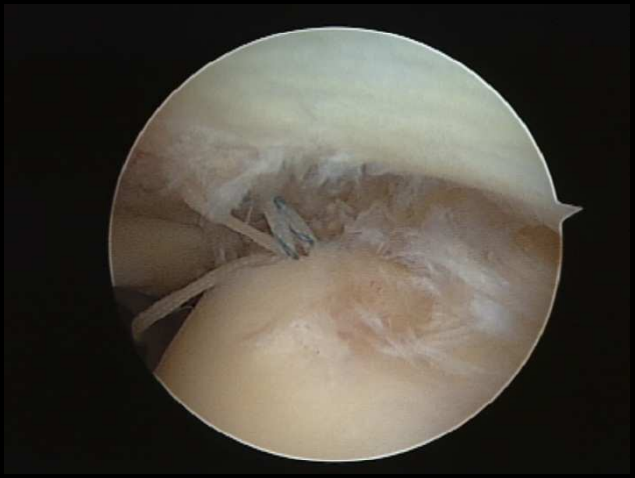

az monica
Orthopedisch centrum SPM

INTERNAL IMPINGEMENT TEAR

Pathomechanism:

- Late cocking phase:

in internal impingement (laxity ant, GIRD, posterior peel back, scapular dyskinesis)

Pathological direct contact between posterior cuff and labrum

az monica
Orthopedisch centrum SPM

INTERNAL IMPINGEMENT TEAR

Pathomechanism

- <u>deceleration / follow through</u> :

eccentric loads on post. labrum and cuff

(108% body weight)

major reason for cuff tears

az monica
Orthopedisch centrum SPM

Cuff tears < 40 years

2 SUBGROUPS

- post-traumatic FT tear supraS
- unique subgroup : ELITE throwers

Internal Impingement

az monica
Orthopedisch centrum SPM

Cuff tears < 40 years

Post traumatic FT tear

previously healthy tendon

respond well to repair in terms of pain relief and self-reported outcomes postop

az monica
Orthopedisch centrum SPM

FULL THICKNESS TEAR

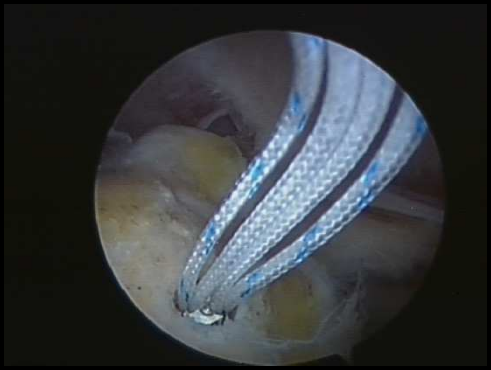

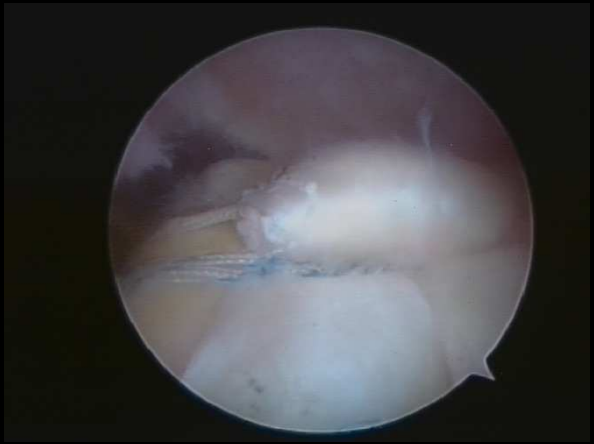

az monica
Orthopedisch centrum SPM

Cuff tears < 40 years

Elite throwers

partial tears due to

chronic overuse

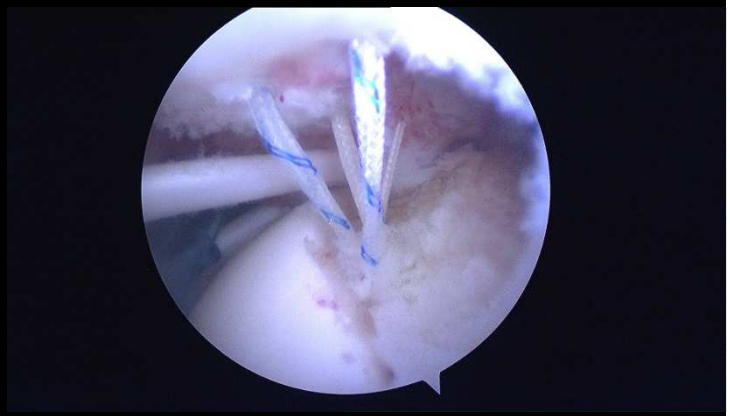

majority good outcome with surgery
but tendancy **poor return to play**

az monica
Orthopedisch centrum SPM

Cuff tears < 40 years

elite throwers

manage differently ??

longer conservative

postop REHAB !!!

in contrast : *non elite throwers* demonstrated a majority of improved outcomes and return to play

az monica
Orthopedisch centrum SPM

Journal of orthopaedic surgery and research (2015)

Sun et al

Which is the best repair of articular-sided rotator cuff tears : a meta-analysis

az monica
Orthopedisch centrum SPM

What is a partial articular tear

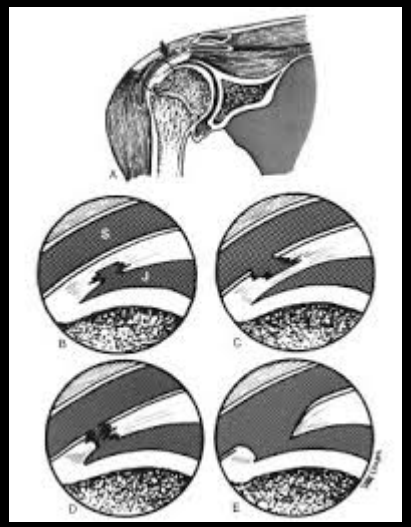

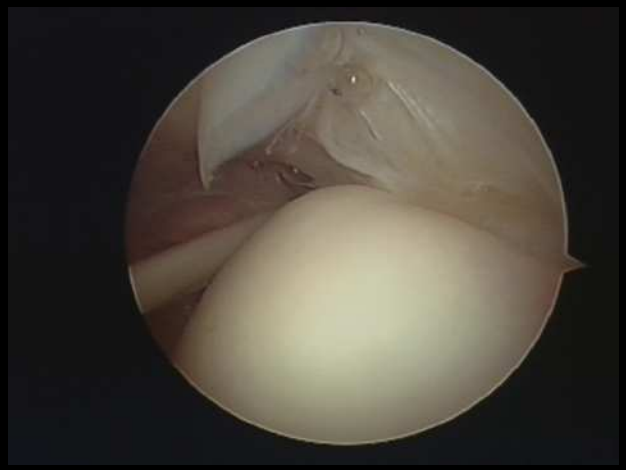

az monica
Orthopedisch centrum SPM

Partial articular cuff tear

articular cuff tear < 50% : conservative trial,

debridement and treat
concomitant lesions

articular cuff tear > 50% :

trans tendon repair

create a full thickness tear

az monica
Orthopedisch centrum SPM

Partial articular tear < 50%

REHAB

az monica
Orthopedisch centrum SPM

Partial articular tear < 50%

handball player

19/9/92

april game : during throw arm was held

10/4/13 : GIRD 20° , slight scapula tilt , Int imp apprehension + , mild loss of power

az monica
Orthopedisch centrum SPM

Partial articular tear < 50%

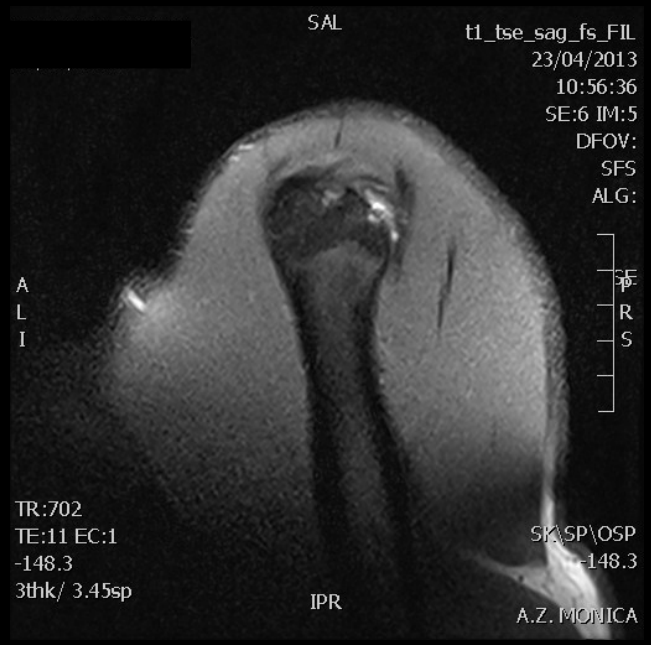

az monica
Orthopedisch centrum SPM

Partial articular tear < 50%

volleyball player , age 27

Exam March : pain since november , no acute onset , pain upperarm , feels click , better with exercise

Impingement ++ , int impingement ++

MRI , REHAB

az monica
Orthopedisch centrum SPM

Partial articular tear < 50%



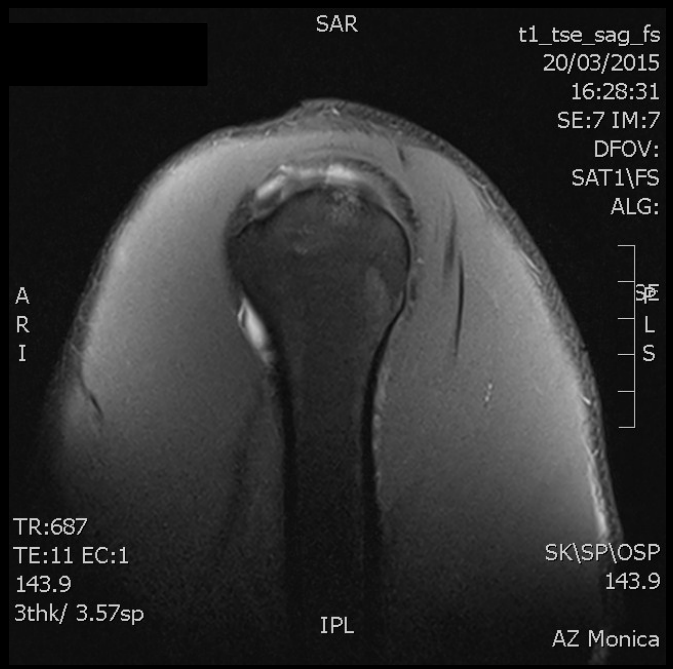

az monica
Orthopedisch centrum SPM

Partial articular tear < 50%

18/5/15 : much better

Impingement - , int imp : still somewhat +

muscular control excellent

Plan : stop volley , career in beach volley

az monica
Orthopedisch centrum SPM

PARTIAL ARTICULAR < 50%

Debridement

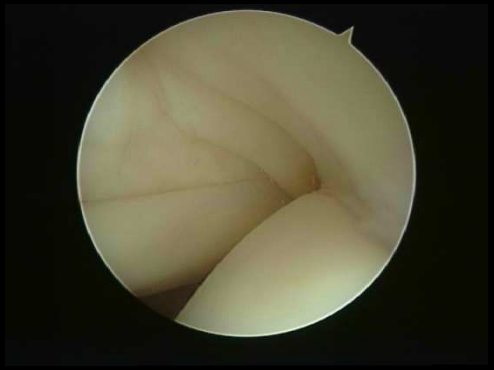

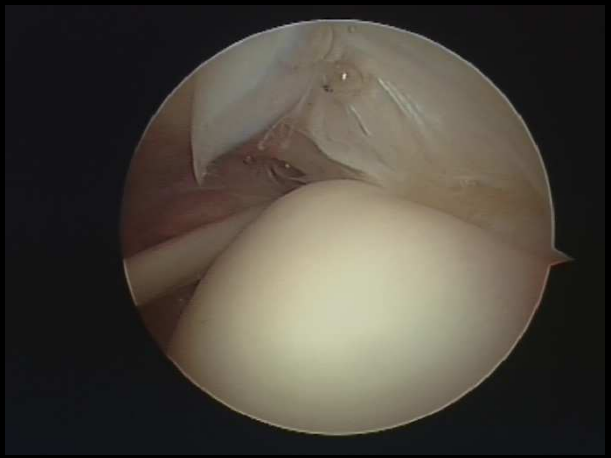

az monica
Orthopedisch centrum SPM

PARTIAL ARTICULAR > 50%

Intra-tendinous repair

create a full thickness repair

az monica
Orthopedisch centrum SPM

PARTIAL ARTICULAR > 50%

Suturing intratendinous

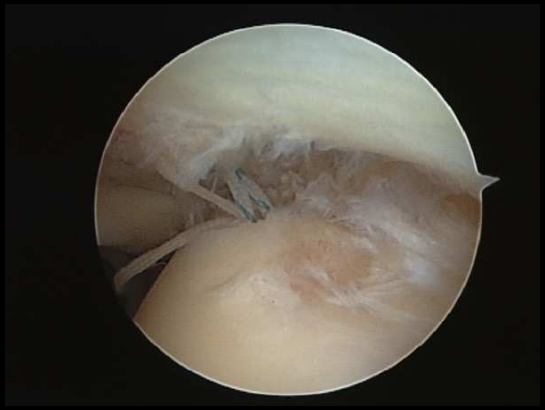

az monica
Orthopedisch centrum SPM

PARTIAL ARTICULAR > 50%

az monica
Orthopedisch centrum SPM

PARTIAL ARTICULAR > 50%

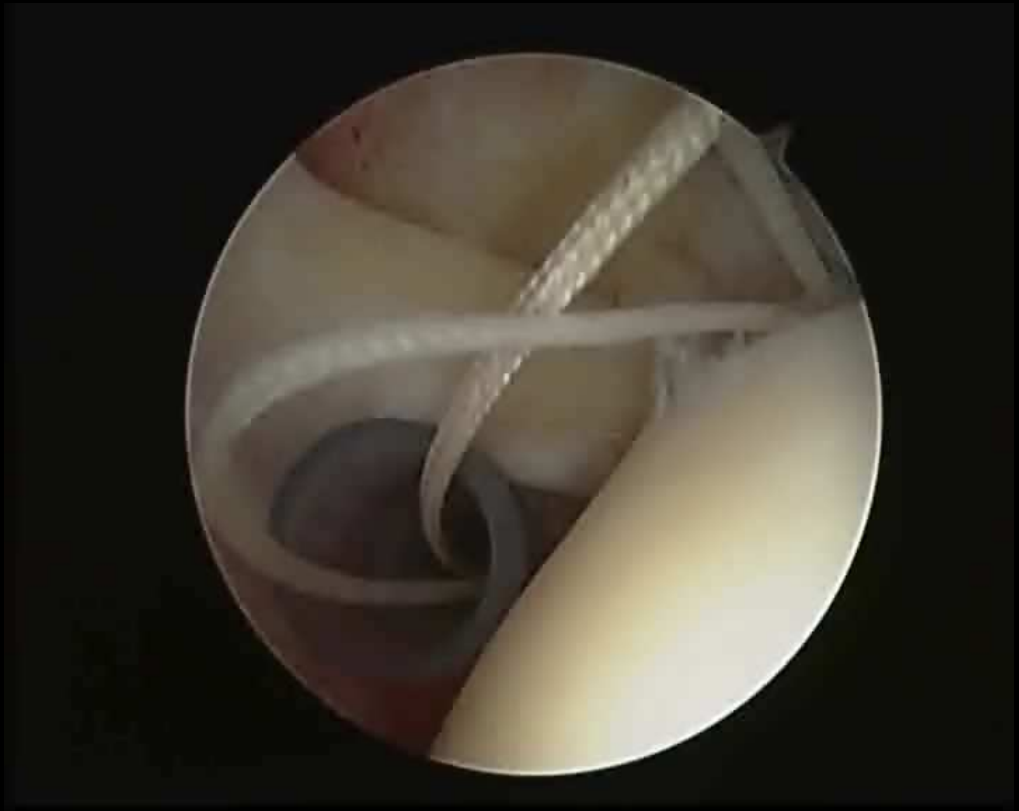

az monica
Orthopedisch centrum SPM

PARTIAL ARTICULAR > 50%

- Create FT tear and treat as FT tear

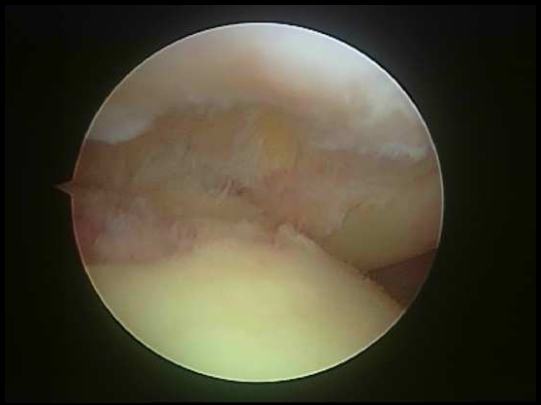

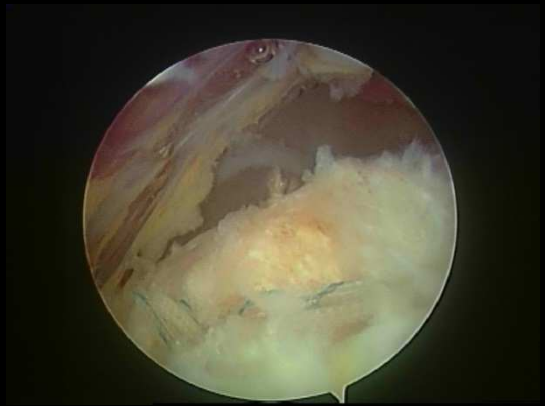

az monica
Orthopedisch centrum SPM

Sun et al

9 studies , 323 patients

All > 50% tendon tears

4 studies tear conversion : 99 patients

7 studies trans-tendon technique : 224 pat

Sun et al

NO DIFFERENCE with regard to ASES scale
(p:0,69)

RE-TEAR rate ($p<0,05$) was markedly lower in the **trans tendon technique** group

az monica
Orthopedisch centrum SPM

Trans-tendon technique

tendon integrity

native footprint

biomechanical properties

are better restored

completion : excises potentially normal tissue

length-tension mismatch

az monica
Orthopedisch centrum SPM

Trans-tendon technique

BUT

pulling a retracted articular layer may overtighten the intact bursal aspect

TTR had more pain and showed a slower functional improvement

az monica
Orthopedisch centrum SPM

PARTIAL ARTICULAR > 50%

az monica
Orthopedisch centrum SPM

PARTIAL ARTICULAR > 50%

az monica
Orthopedisch centrum SPM

PARTIAL ARTICULAR > 50%

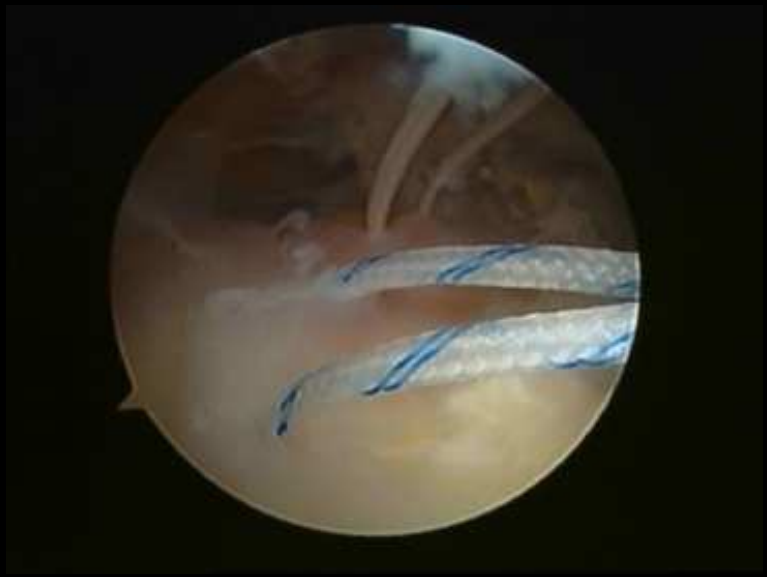

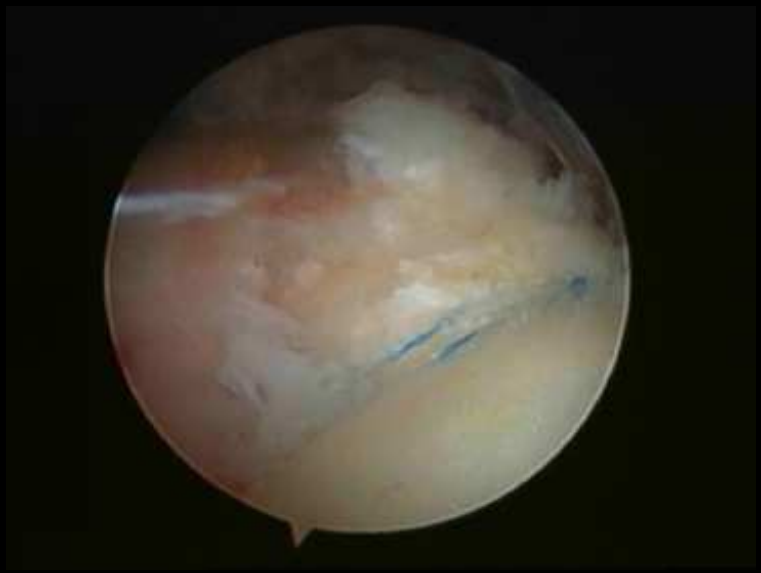

az monica
Orthopedisch centrum SPM

J Pediatr Orthop B. 2013 March
Weiss JM

Rotator cuff injuries in adolescent athletes

the cause of tears in the young athlete has been described as an overuse injury related to internal impingement

az monica
Orthopedisch centrum SPM

Adolescents

7 patients

2 tear subscap tendon , 2 avulsion fracture LT
1 torn rotator interval , 1 supraS tear ,
1 avulsed GT

only 4 recalled a specific traumatic event

6 had an operation , 1 rehab

once injury identified and treated prognosis very good

az monica
Orthopedisch centrum SPM

Example of adolescent injury

male 6/7/99

summer 2014 : Ski-slide ,

landed on the left arm

local hospital : XR-

Nearly 1 year later instability complaints , feeling click

exam : apprehension +

A-MRI : bony subscap tear

az monica
Orthopedisch centrum SPM

Example of adolescent injury

MRI

az monica
Orthopedisch centrum SPM

Example of adolescent injury

Renewed clinical exam

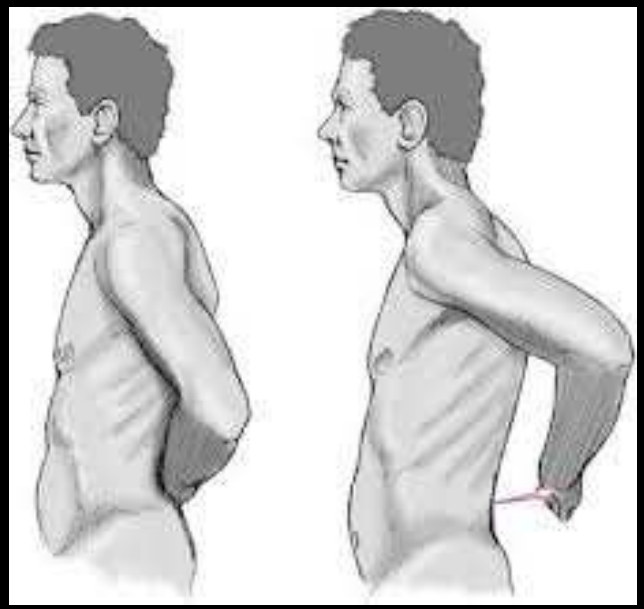

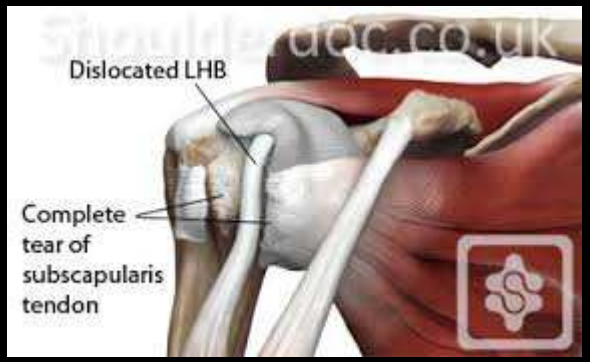

az monica
Orthopedisch centrum SPM

Example of adolescent injury

operation 4/6/15 : open repair

four anchor fixation double row

clinical exam 6 weeks postop

XR : consolidation

160° active elevation

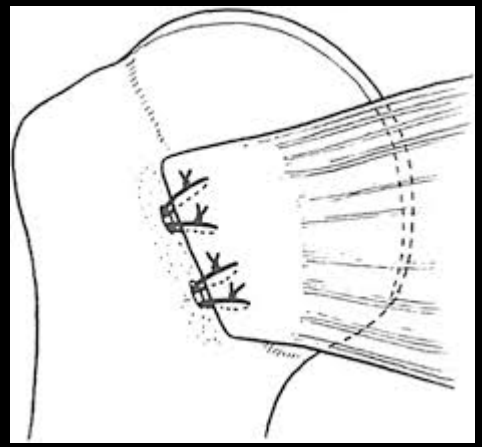

az monica
Orthopedisch centrum SPM

Example of adolescent injury

pre-post XR

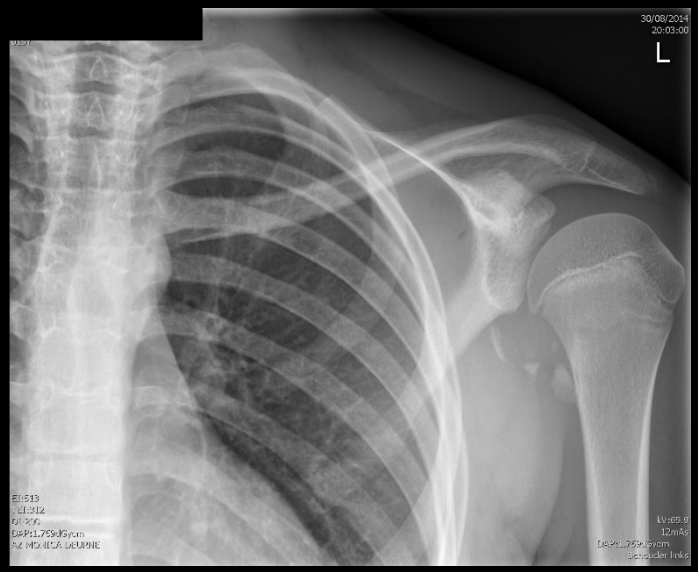

az monica
Orthopedisch centrum SPM

Summary

rotator cuff tear in young patients :
DIFFERENT DISEASE

2 type of lesions

- post traumatic cuff tear
- articular chronic overuse tear

CAVE : youngsters

ROLE OF FUNCTIONAL REHAB

az monica
Orthopedisch centrum SPM

Thank you

az monica
Orthopedisch centrum SPM